

## Twitter Thread by [Maryjane Sugar](#)

[Maryjane Sugar](#)

[@Sugarsmooth69](#)



**My name is Maryjane and the woman in the picture is Okolo Beatrice, my mother.**

**In August, my mom started having constant headaches. She went to the hospital, and was attended to by a doctor, but the headache persisted.**

At a point, she started having loss of memory and disorientation.

We were asked to go to the Neuropsychiatric hospital to ask for a Neurologist.

She went, but did not see a Neurologist on seat, but met with another doctor there.

She was given some medications and asked to come back in a month. She returned to the hospital on the 29th of September with the same complaints. She was given medications again and was sent back home.

At a point I was no longer comfortable with the complaints.

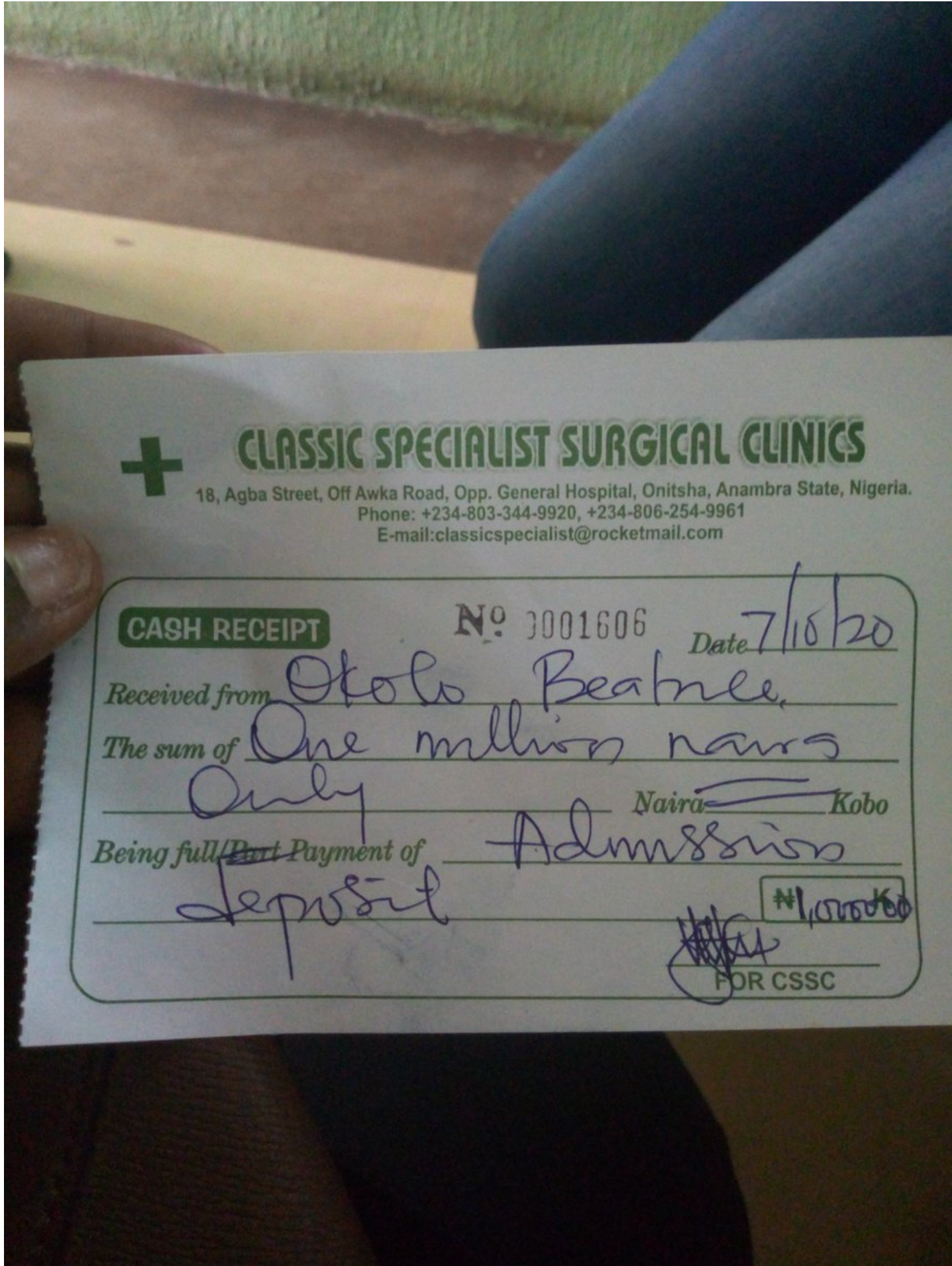
I assumed it was a result of stress. So on the 1st of October, I went to my parents house, picked her up and went straight to the lab, where blood work as suggested by a doctor was carried out. From the lab, I took her to my house. My plan was for her to rest well.

The results of the test came back on the 4th of October, and the outcome prompted me to start looking for a Neurologist. I started making calls. Fortunately, we got a number and the following day which was the 5th of October, I took her to the doctor in Onitsha.

We were sent for a CT head scan at Sun diagnostic center, Onitsha. The films came out but we were asked to come in for the report the following day. (In the 6th of October) by 2pm. The films were then sent to the doctor.

On our way back from the hospital, the junior doctor called to tell me the worst news of my life. My mother has been diagnosed with Glioblastoma and needs urgent surgery. We were asked to deposit 1 million naira for the surgery immediately.

After so many running around, we were able to come up with the money. We made a deposit. By then it was around 7pm and we were asked to come the following day.



**+** **CLASSIC SPECIALIST SURGICAL CLINICS**

18, Agba Street, Off Awka Road, Opp. General Hospital, Onitsha, Anambra State, Nigeria.  
Phone: +234-803-344-9920, +234-806-254-9961  
E-mail: classicsspecialist@rocketmail.com

**CASH RECEIPT**

No. 0001606

Date 7/10/20

Received from Okolo Beatrice

The sum of One million naira

Only Naira                      Kobo

Being full/Part Payment of Admission

deposit

**#1,000,000**

*[Signature]*

FOR CSSC

My mom's health started getting worse that night. We didn't sleep throughout the night. She vomited all night and by morning she became unconscious. We rushed her to the hospital and she was admitted. Later we were asked to take her to another branch of the hospital in Awka.

This was because the surgery couldn't be performed in the current branch. I went back to the lab to get the report of the CT scan but it wasn't ready yet. My mum was critical and I was being told to come back later for a report that was supposed to be ready.

Ready in time for surgery. They asked for my email and told me once the result is ready, it will be sent to me. I got it later that day and forwarded it to the doctor. We were told that the Intracranial pressure was high she'll need to be stabilized before surgery.



# SUN MEDICAL DIAGNOSTICS

MEDICAL LABORATORY AND RADIOLOGY IMAGING

Patient Id	MRN 892	Name	OKOLO BEATRICE A.	Accession No	
Study Date	05-Oct-2020	Age	56Y	Gender	Female

## CT SCAN OF BRAIN

**Axial plain and post contrast CT scan of the brain has been performed using 5mm contiguous slices**

### OBSERVATIONS:

An ill-defined peripherally enhancing hypodense lesion is seen in the left temporo-parietal region and measures approximately 5cm anteroposteriorly, 4cm transversely. Mass-effect is seen on the left lateral ventricle with shift of the midline to the right by approximately 15mm.

The rest of the supratentorial brain parenchyma is normal.

No other focal area of abnormal attenuation is identified in the supratentorial parenchyma.

No focal cerebellar or brain stem lesion is seen.

The ventricular system is normal.

The calvarium appears normal.

Bone window settings do not reveal any fracture.

The sella and parasellar structures are normal.

### IMPRESSION:

- **Lesion in the left temporo-parietal region with perilesional oedema and midline shift to the right. The differentials include brain abscess/neoplasm.**

Electronically signed by DR AMOL KHANDELWAL DMRD. CERTIFIED BY DNB, Consultant Radiologist  
Investigations have their limitations. Solitary pathological/Radiological and other investigations never confirm the final diagnosis.  
They only help in diagnosing the disease in correlation to clinical symptoms and other related tests. Please interpret accordingly.

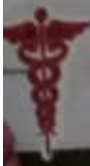For further enquiries on this radiological result(s) : + 2348036886800.

After so many medical interventions, she regained consciousness and was booked for surgery on the 10th of October. My mom was in the theatre for 9 hours. Immediately she came out of the theatre, she was sent for a CT scan. We were told the report will be out in 3 days time.

The doctor told us that the tumor was so extensive. That they brought out the much they could without causing more harm to her. The tissue was now sent to Pathocon lab in Nnewi for histological studies. Within the coming week, we ran so many blood works.

Yet she wasn't getting any better. Her head was swollen. The report of the CT scan revealed haemorrhage and air pockets which needed attention.

On Sunday the 18th, I received a call that we are supposed to pay another deposit. My mom will be going for another surgery.



# ELDORADO DIAGNOSTIC AND RESEARCH CENTER

# 3 Onyeali Street, Nodu Okpuno, Behind Central Bank Express Awka, Anambra State.

Tel: 08062930742

E-mail: [eldoradomultispecialist@yahoo.co.uk](mailto:eldoradomultispecialist@yahoo.co.uk)

Year Ref

Date

NAME: OKOLO BEATRICE

AGE : 56YEARS

SEX : FEMALE

DATE: 10/10/2020

## CRANIAL CT SCAN

PROTOCOL: Serial pre and post contrast enhanced axial CT images were acquired at 5.0mm cuts from the floor of the maxillary anthra through the brain to the vertex. Coronal and sagittal reformatting and volume rendering were also done.

FINDINGS: There is no pre-interventional CT images for comparison.

There is a hyperattenuating (67HU) lesion with associated area of hypoattenuation in the left temporo-parietal lobes. There is associated ipsilateral sulcal effacement as well as effacement of all the components of the left lateral and 3<sup>rd</sup> ventricles and shift of the brain midline structures to the right. There are intracranial air densities in the left fronto-temporo-parietal lobes as well as in the overlying scalp in the temporo-parietal regions. The right cerebral hemisphere, cerebellum, midbrain and Pons are normal.

The right lateral and 4<sup>th</sup> ventricles and basal cisterns are within normal limits.

The paranasal sinuses, mastoid air cells, eye globes and retrobulbar structures are normal.

*Motto: Quality Health Care in a Friendly Environment*



Money was paid and surgery done.

Histology result came out and it wasn't a malignant glioblastoma as was initially diagnosed. It's pilocytic Astrocytoma, a benign tumor. I was like "yeah, this is great news, we'll still need to do 1 or 2 radiation and she'll be fine"

*...lending hand to your exquisite clinical management.*  
**PATHOCON SPECIALIST CLINIC AND RESEARCH INSTITUTE**  
 NO. 34, NNOBI ROAD, NNEWI  
 PHONE: 08073451430; 08169479856  
**LABORATORY REPORT FORM**

<u>SURNAME (CAPITAL):</u> OKOLO	<u>Other Name(s):</u> Beatrice	<u>Hospital No.:</u> ???	<u>Sex/Age:</u> F/56 yrs	<u>Tribe/Race:</u> Igbo/Black
<u>Nature/Location of Specimen(s):</u> Left temporal Intra-axial brain tumour		<u>Request:</u> Histology	<u>Laboratory No.:</u> H20/1027	
<u>Name/Address of Hospital:</u> Classic Specialist Surgical Hospital & Clinics, Aw			<u>Physician/Surgeon:</u> Prof. JKC. Emegulu	
<u>Date of Collection:</u> ??/10/2020	<u>Date Received/Grossed:</u> 12/10/2020//12/10/2020	<u>Date Reported:</u> 21/10/2020		

**CLINICAL SUMMARY:** Memory loss for two years. Has headache for one year. No preceding history of trauma. Nil weight loss, seizure, anorexia, nausea or vomiting. Nil chronic cough, including night sweats or contact with a chronically coughing adult. Nil obvious cranial nerve deficit.


**Results of Relevant Diagnostic Investigation:** Cranial CT scan showed an irregularly per lesional oedema.

**Provisional Diagnosis:** Left temporal intra-axial tumour ? Brain mass rule out GBM.

**MACROSCOPY:** Received are three pieces of grayish soft tissue with some brownish tinge, altogether weighing 6g and measuring 3.0x2.5x1.0cm. Cut section show grayish white surfaces with areas of degeneration. Representative sample (5 blocks) of the specimens were submitted for processing.

**MICROSCOPY:** Sections of fragmented tissue show a neoplasm with biphasic hypercellular and hypocellular areas composed of cells some of which have vacuolated cytoplasm and polygonal nuclei lacking atypicality, laid on vascular and fibrillary background. Areas of infarct and haemorrhage are seen. No features suggesting glioblastoma is seen. **Features are in-keeping with a glioma, favour Pilocytic Astrocytoma.**

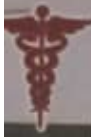*Left temporal tumour: Read text*

  
**Prof. I.V. Onyiaorah**  
 Consultant Pathologist

*Consultants: Prof. I.V. Onyiaorah, & Prof. C.O. Ukah*

But how wrong I was. In the following weeks, her health has deteriorated and the neurologist wants to transfer her to a radiation treatment center at UNTH.

The doctor said the recent CT scan done revealed that there are still little tumors coming up.



# ELDORADO DIAGNOSTIC AND RESEARCH CENTER

# 3 Orywell Street, Nedu Okpuno, Behind Central Bank Express Awka, Anambra State.

Tel: 08062930742

E-mail: [eldoradomultispecialsit@yahoo.co.uk](mailto:eldoradomultispecialsit@yahoo.co.uk)

Case Ref

Year Ref

Date

Director

BOARD

in Board

MEMBER

MD (MR)

(MR)

NAME: OKOLO BEATRICE A.  
AGE: 56 YEARS  
GENDER: FEMALE  
DATE: 02/12/2020

## CRANIAL CT

Post-operative Images acquired: 21/11/2020  
Reported 02/12/2020  
No pre-intervention images available for comparison.

Serial non contrast and post contrast axial images were acquired at 5.0mm cuts at the skull base and through the brain to the vertex. Sagittal, coronal and axial reformatting done at 1.25mm cuts. (volume images).

Bone and Soft tissue window images show three small cranial bone defects at the left fronto-temporo-parietal region (1.5cm AP), the ipsilateral temporo-parieto-occipital region (0.9cm AP) and along the left parietal bone on higher cuts (0.8cm AP), all likely craniotomy defects. Multiple, small, intracranial hypodense areas of varying sizes noted at regions of the aforementioned, small, cranial bone defects, possibly epidural or subdural aeroceles, appreciated only on Brain window images. Largest of these noted anteriorly, measuring 1.8cm x 0.7cm (AP x TS).

Brain window images show an ill-defined, non-enhancing, hypodense area straddling the cortical and subcortical aspects of the left fronto-temporo-parietal regions (HU 20.5 average), measuring 7.6cm x 3.5cm (AP x TS). There is a fairly oval shaped, ring enhancing hypodense area noted within the left temporal lobe measuring 1.8cm x 1.1cm (LS x TS). Similar but smaller ring enhancing hypodense area also noted antero-inferiorly within same left temporal lobe, measuring 1.5cm x 0.9cm (AP x TS). No definite, associated mass effect appreciated at this time.

*Motto: Quality Health Care in a Friendly Environment*

But I took the recent report to another doctor for a second opinion and I was told that the only option we have now is to send mom to Memfys Neuro hospital Enugu. That they have the best hands that can help our case.

On enquires about the radiation and Memfys hospital, I found out that I can not afford any other treatment as her previous treatment has depleted our sources. We've also accumulated another 3.6 million apart from all the money we've paid so far in the recent hospital.

This is the reason I'm pleading with anyone who comes across this link to help donate any amount you can spare, to help my mom.

■500 by 20k people will give me 10 million naira. It's a great start. I know things are hard, but I beg y'all. My mum is just 56, still in her prime.

I opened a GoFundMe account yesterday. I'll post the link in the next space. For people who find the GoFundMe stressful, My account details are 3034769154  
Nwonwu Maryjane Chinaza  
First bank

@aproko\_doctor @DrOlufunmilayo

Sorry for the tags. Please help me share.

Thank you so much everyone.

Hi there,

I'd really appreciate it if you could share or donate to this GoFundMe,

\*Help my mom regain consciousness and live again\*

<https://t.co/3TjATw98lb>